

CLINICAL QUIZ

Right Iliac Fossa Pain in Elderly: Always Appendicitis?

NAZARI F¹, HAYATI F², AZIZAN N³, TEH YG⁴, MOHD DAUD MN⁵

¹Department of Surgery, Queen Elizabeth Hospital, Ministry of Health Malaysia, Kota Kinabalu, Sabah, Malaysia

²Department of Surgery, ³Department of Pathobiology and Medical Diagnostic, ⁴Department of Medicine, ⁵Department of Community and Family Medicine, Faculty of Medicine and Health Sciences, Universiti Malaysia Sabah, Kota Kinabalu, Sabah, Malaysia

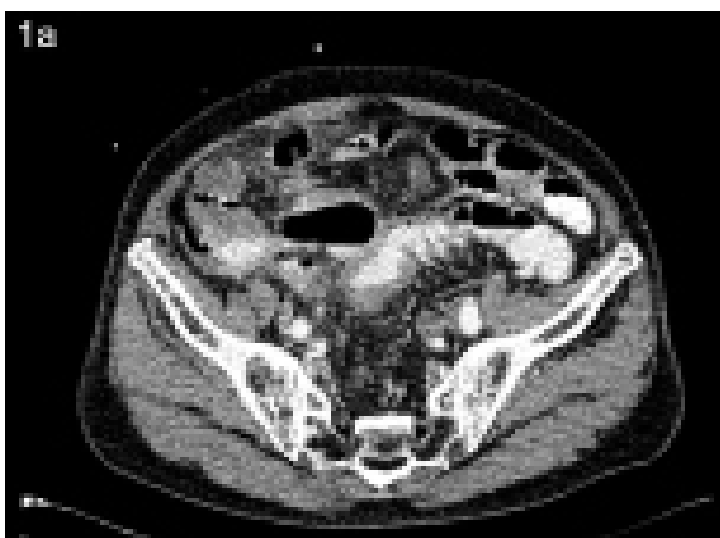

Figure 1a: Contrast enhanced computed tomography showing diffuse thickening of the rectosigmoid colon

Address for correspondence and reprint requests: Firdaus Hayati. Department of Surgery, Faculty of Medicine and Health Sciences, Universiti Malaysia Sabah, Kota Kinabalu, Sabah, Malaysia. Tel: +088-320000 ext. 611029 E-mail: firdaushayati@gmail.com

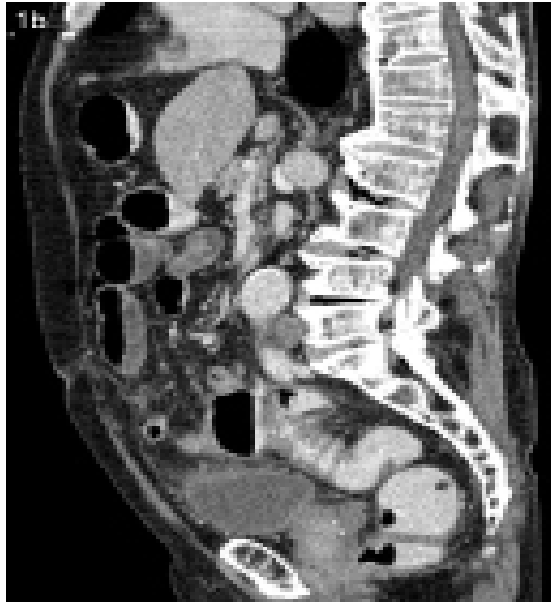


Figure 1b: Computed tomography in sagittal view showing diffuse thickening of the rectosigmoid colon with fat streakiness

QUESTION

A 76-year-old male, previously well, presented with acute, non-migratory right iliac fossa pain for a week. He denied per rectal bleeding, production of mucus, or constitutional symptoms but complained of constipation since 6 months ago. Upon assessment, he was septic with localized guarding at the right iliac fossa. A contrast enhanced computed tomography was obtained (Figure 1a and 1b). Spot the radiological diagnosis and briefly discuss the sequelae of this condition?